

EUROPEAN JOURNAL OF CARDIO-THORACIC SURGERY

**Surgical angioplasty of the left main coronary artery and/or proximal segment of the
right coronary artery by pulmonary autograft patch**

Michael Malyshev, Igor Gladyshev, Alexander Safuanov, Dmitry Siniukov, Dmitry
Borovikov and Natalie Rostovykh

Eur J Cardiothorac Surg 2004;25:21-25

DOI: 10.1016/j.ejcts.2003.09.017

This information is current as of July 11, 2010

The online version of this article, along with updated information and services, is located on
the World Wide Web at:

<http://ejcts.ctsnetjournals.org/cgi/content/full/25/1/21>

The European Journal of Cardio-thoracic Surgery is the official Journal of the European Association for
Cardio-thoracic Surgery and the European Society of Thoracic Surgeons. Copyright © 2004 by European
Association for Cardio-Thoracic Surgery. Published by Elsevier. All rights reserved. Print ISSN:
1010-7940.



ELSEVIER

European Journal of Cardio-thoracic Surgery 25 (2004) 21–25

EUROPEAN JOURNAL OF
CARDIO-THORACIC
SURGERY

www.elsevier.com/locate/ejcts

Surgical angioplasty of the left main coronary artery and/or proximal segment of the right coronary artery by pulmonary autograft patch[☆]

Michael Malyshev*, Igor Gladyshev, Alexander Safuanov,
Dmitry Siniukov, Dmitry Borovikov, Natalie Rostovykh

Center of Cardiac Surgery of Chelyabinsk's Railroad Clinical Hospital, P.O. Box 5977, ul. Dovatora, 23, Chelyabinsk 454048, Russia

Received 25 July 2003; received in revised form 9 September 2003; accepted 16 September 2003

Abstract

Objectives: There are controversial opinions about the expediency of performance of the surgical angioplasty of the left main coronary artery (LMCA) and/or proximal segment of the right coronary artery (RCA) in rare cases of isolated lesion or with limited involving of distal coronary branches. One of the many fears restraining a wider performance of this operation is the uncertainty in longevity of patch material. It is supposed that the autovein has tendency to proliferating degeneration similar to that in case of coronary artery bypass grafting (CABG), while the autopericardium may be subjected to calcification. Autoarterial patches have a limited width. To withdraw these real or hypothetical negative properties of patch materials we offer to harvest the pulmonary autograft patch (PAP) for coronary angioplasty. **Methods:** Our experience with PAP-angioplasty of LMCA and/or proximal segment of RCA includes four cases. Simultaneous angioplasty of LMCA and proximal segment of RCA was performed in one patient; angioplasty of LMCA – in two patients; angioplasty of RCA – in one patient. In two cases the stenosis of LMCA was accompanied by stenotic lesion of left anterior descending coronary artery (LAD). The surgical approach to LMCA was performed by complete crossing of pulmonary artery (PA). There was no necessity to use any plastic material for restoring of PA integrity in all cases. **Results:** All patients survived after the operation. The postoperative course was uncomplicated except one case of LMCA/LAD lesion. There was a temporary low cardiac output syndrome and ventricular arrhythmia resulting in additional CABG as 'back-up' procedure. This complication was not a consequence of impassability of LMCA because its good patency was established at control coronary angiograms. The postoperative coronary angiograms were performed in all cases. They showed a satisfactory width of the main coronary vessels. The maximal follow-up period is 30 months. **Conclusion:** We suppose that the use of viable pulmonary autograft patch for surgical angioplasty of LMCA and proximal segment of RCA removes one of a lot of fears, which restrain the wider use of this alternative to CABG operation.

© 2003 Elsevier B.V. All rights reserved.

Keywords: Coronary artery surgery; Left main coronary artery; Surgical angioplasty; Right coronary trunk; Patch angioplasty

1. Introduction

After some period of oblivion surgical patch angioplasty of the left main coronary artery (LMCA) was revived by Hitchcock et al. [1]. Soon this operation was revived for correction of the stenosis of the proximal segment of the right coronary artery (RCA) [2]. There are still controversial opinions about the expediency of the performance of this

procedure in rare cases of isolated lesion of LMCA/RCA or with limited involving distal coronary branches [3,4]. One of the fears giving doubt in the possibility of a reliable performance of the surgical angioplasty is the uncertainty in longevity of patch materials [5]. It is supposed that the autovein has tendency to proliferative degeneration similar to that in case of coronary artery bypass grafting (CABG) [6] or to dilating because of its natural elasticity [7]. At the same time the autopericardium may be subjected to calcification (Appendix A to ref. [8]) and does not have fibrinolytic properties [9]. Autoarterial patches have a limited width. To withdraw these real or hypothetical negative properties of patch materials we offer to harvest the pulmonary autograft patch (PAP) for coronary angioplasty.

[☆] Presented at the joint 17th Annual Meeting of the European Association for Cardio-thoracic Surgery and the 11th Annual Meeting of the European Society of Thoracic Surgeons, Vienna, Austria, October 12–15, 2003.

* Corresponding author. Tel.: +7-3512-687-811; fax: +7-3512-616-767.
E-mail address: cardiosur@chel.surnet.ru (M. Malyshev).

Table 1
Patients' perioperative characteristics and risk factors

Patient	Age (years)	Sex	Risk factors	LV function	Symptoms	Date of operation	Coronary lesion	Surgical procedure	The time of postoperative CAG (months)	Follow-up (months)
1	44	M	Hyperlipidemia heavy smoker	Preserved	Class III angina	12/2000	LMCA (middle third) LAD	Surgical angioplasty of LMCA by PAP, LIMA-LAD shunt	5	30
2	43	M	Hyperlipidemia hypertension heavy smoker	Preserved	Class IY angina	03/2001	LMCA (ostium) RCA (ostium)	Surgical angioplasty of LMCA and RCA by PAP	2	27
3	45	M	Hyperlipidemia hypertension heavy smoker	Preserved	Class IY angina	01/2002	LMCA (middle third) LAD	Surgical angioplasty of LMCA by PAP, LIMA LAD shung Additional autovein shunts to DB and OM coronary branches	1	17
4	53	M	Hypertension AMI in history heavy smoker	Preserved	Class IY angina	09/2002	RCA (ostium)	Surgical angioplasty of RCA by PAP	1	9

AMI, acute myocardial infarction; LAD, left anterior descending coronary artery; LIMA, left internal mammary artery; LMCA, left main coronary artery; RCA, right coronary artery; PAP, pulmonary autograft patch; CAG, coronary angiography; DB, diagonal coronary branch; and OM, obtuse marginal coronary branch.

This report contains our experience in PAP angioplasty of LMCA and/or proximal segment of RCA.

2. Material and methods

The excellent results reported by Dion et al. [2,8], Jegaden et al. [7] and others encouraged us to perform surgical angioplasty of right and left coronary trunks, or

both, since 1998. We have experience in 11 cases of patch angioplasty of main coronary vessels with maximal follow-up period 57 months. Since December, 2000 we have applied a harvest of angioplastic patch from the pulmonary artery. At present time our limited experience with PAP-angioplasty of LMCA and/or proximal segment RCA includes four cases. Patients' perioperative characteristics and coronary risk factors are listed in Table 1.

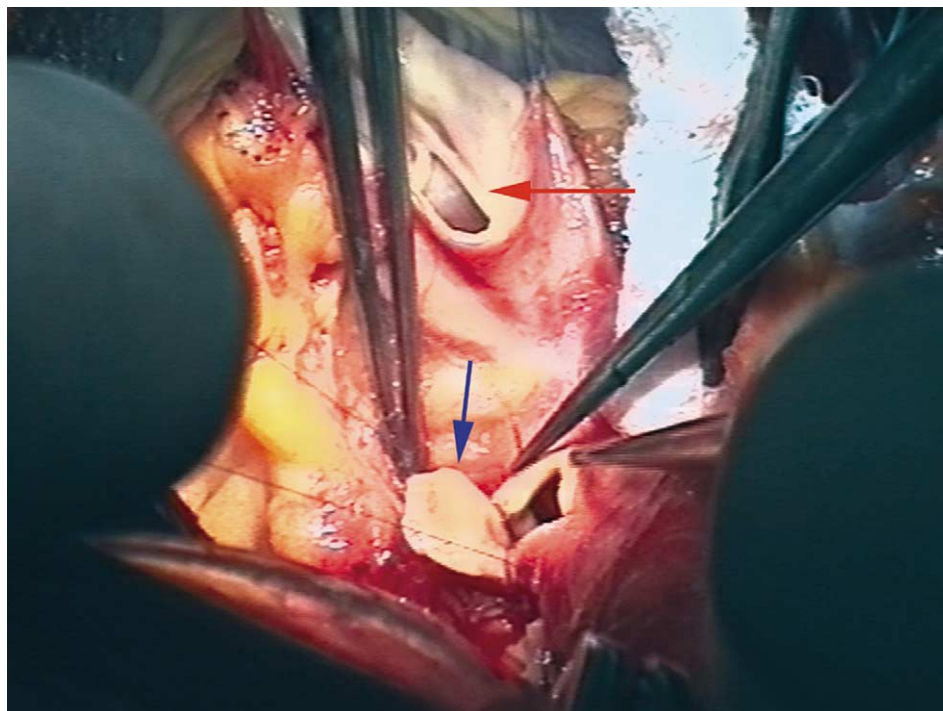


Fig. 1. The angioplasty of LMCA by the pulmonary autograft patch (the patient N3 – the view from the patient's head). Blue arrow – the creation of the 'funnel'-shaped entrance into LMCA; and red arrow – the proximal part of the completely crossed pulmonary trunk.

Surgery was performed using a standard balanced fentanyl anesthesia. Myocardial preservation includes moderate hypothermic (30°C) cardiopulmonary bypass, aortic cross-clamping and cardiac arrest by cold blood antegrade intermittent cardioplegia in combination with topical cooling with ice cold saline. The left ventricle was vented through the right superior pulmonary vein. The time of aortic cross-clamping was 38, 101, 80, 42 min; the CPB time was 79, 138, 129, 74 min correspondingly.

In all cases of PAP-angioplasty of LMCA we used the anterior approach with complete crossing of the main pulmonary artery. The tailoring of a pulmonary autograft patch was performed predominately from the anterior pulmonary artery wall or by wider (up to circular) cutting in case of biostial lesion. In cases of LMCA PAP-angioplasty we followed the methodology of Dion et al. [8], consisting of creation of a ‘funnel’ shape of the entrance into LMCA with a wide angioplastic patch (Fig. 1).

In cases of RCA PAP-angioplasty, before the CPB the proximal segment of RCA was dissected through the fat of the epicardium from its aortic origin. The procedure was performed by direct longitudinal opening of the RCA lumen with cutting enough far along aortic wall. The length of the opening of RCA and the adjoining aortic wall sometimes achieved more than 3 cm. Although the creation of a wide ‘funnel’ shape entrance has less importance in case of angioplasty of RCA in comparison with LMCA, we try to do this independently on the right or left angioplasty performance. The endarterectomy was avoided in all cases.

The restoration of the pulmonary artery integrity was carried out in all cases by a simple double continuous prolene suture without any graft materials.

3. Results

All patients survived after the operation. The post-operative course was uncomplicated in all cases except one with stenosis of LMCA and left anterior descending coronary artery (LAD) (N3). There were problems with his weaning from cardiopulmonary bypass. This patient demonstrated low cardiac output and ventricular arrhythmia. We were sure that the patient’s condition was not consequence of poor patency of the proximal part of LMCA because it was determined by transesophageal echocardiography. But we did not exclude the possibility of a poor patency of distal parts of the left stem, that was why we performed the back-up CABG to obtuse marginal and large diagonal coronary branches. There was a good patency of LMCA and all ‘back-up’ shunts at the control postoperative coronary angiograms.

The control coronary angiography was carried out in all cases. It showed a sufficient width of angioplasty subjected vessels (Fig. 2).

The maximal follow-up period is 30 months.

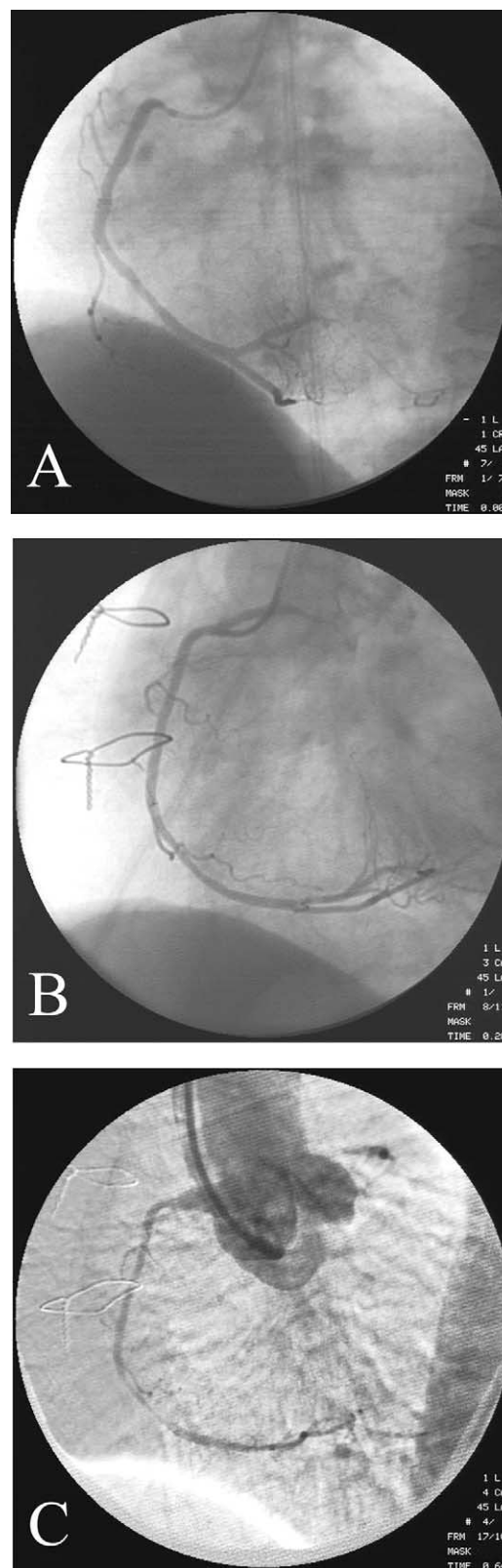


Fig. 2. Coronary angiograms of RCA before (A) and after (B) PAP-angioplasty (the patient N4). (C) Aortic angiogram showing the ‘funnel’ shape of the entrance into the RCA.

4. Discussion

The surgical patch angioplasty has a lot of more superior properties in comparison with conventional CABG in the surgical management of stenosis of LMCA and/or proximal segment of RCA [10–13]. At the same time, still there are controversial opinions in published articles about the expediency of the performance of this procedure due to the possibility of development of restenosis in this area with dangerous consequences (discussion in ref. [1], [3,4,14,15]). Despite encouraging follow-up results with venous and pericardial patch in Dion's series [8], some authors fear the development of restenosis after patch angioplasty because of negative properties of different patch materials (discussion in ref. [16]). It is supposed that autovein has tendency to specific proliferative degeneration as it is in case of CABG ([6], discussion in ref. [15]) and has a property to dilate because of its natural elasticity [7]. A fresh autopericardium does not have fibronolitic properties [9] but has a possibility of later shrinkage with an unpredictable behavior of the coronary entrance [17]. To avoid this negative property of a fresh autopericardium, some surgeons treat it with 0.6% solution of glutaraldehyde for 5–30 min [17–20], but this treatment gives a new condition of tissue – to be subjected to calcification (discussion in ref. [15]).

We have reviewed the published data about the performance of patch angioplasty of main coronary vessels since the time of reviving of this procedure in 1983 [1] with accentuation of the kind of patch material used and the rate of restenotic failure (Table 2). There are definite limitations for the recognition of these data as a statistical parameter because the authors of these articles did not always have special purposes to determine the rate of restenotic failure and to assess the follow-up results. However it may be recognized as a certain marker for an approximate assessment of different patch materials. As one can see from Table 2, the rate of restenotic failure in the autovein patch group is about 3.4% (five cases of restenosis to 147 operations). While in the group including all kinds of autopericardium patch this marker is about 4.9% (five cases to 102 operations). This difference is not great, which results in the difficulty to choose the best kind of patch material.

It determines that the same author often uses both kinds of popular patch materials without any preferences [8,15,21].

The encouraging results have been achieved with the use of autoarterial patches harvested from the distal segment of the left internal mammary artery [22] or proximal segment of the right internal mammary artery [5,23] but the number of these cases is small and the follow-up results are not yet assessed. At the same time, the width of the internal mammary artery patch may be insufficient to perform a safe extensive patch angioplasty of LMCA. If to accept the pattern of LMCA angioplasty, proposed by the most experienced in this field Dion et al. [8], the sufficient width of patch plays an important role in creation of funnel-shaped LMCA ostium [24]. There is an acute angle formed by the junction between the axis of LMCA and the aortic wall at the anterior approach, giving the best visualization of all LMCA parts. It is demanded to create angioplasty with an extensive patch to avoid the patch kinking and the restenosis at this point. Besides that, the expanding of the internal mammary artery for patch angioplasty excepts its use for CABG in case of a new distal coronary stenosis in the future.

We offer the alternative material for angioplastic patch – the wall of autopulmonary artery. In comparison with autovein and autopericardium, the theoretical advantage of an autopulmonary wall is the uniform embryologic origin with the wall of the aorta. The embryologic formation of aorta and of the main pulmonary artery occurs by partitioning of the aortic embryologic sac into aortic and pulmonary pathways [25]. The uniform embryologic origin means the similar properties of the endothelium of the vessel walls, especially concerning the abilities to produce fibrinolytic effect and for transluminal nutrition of the endothelial cells. The longevity of pulmonary autograft in Ross procedure proves the possibility of transluminal nutrition of the autograft tissues.

One more advantage of pulmonary autograft is that tailoring of an angioplastic patch does not have size limitations and is able to give any patch shapes. At the same time, the elastic properties of the pulmonary artery allow to restore its integrity without using any plastic material.

At last, if the anterior approach is used with complete dividing of PA the harvesting of the patch performs in

Table 2

Review of the patch materials for surgical angioplasty LMCA/RCA (from the published articles since 1983 to present time)

The kinds of patch material								
Fresh autopericardium	Glutaraldehyde treated autopericardium	Autopericardium without specification	Bovine pericardium	Autovein	Synthetic material (PTFE, Dacron)	Internal mammary artery	Radial artery	Unspecified patch material
52 (1)** 102 (5)**	22 (2)	28 (2)	1	147 (5)	2	22 (0)	1	7

* – the digits without brackets – total number of cases; and ** – the digits in brackets – the restenotic failure cases.

passing without the appearance of an additional stage in the procedure.

Thus, it may be assumed that the pulmonary autograft patch is an alive tissue with a simultaneously excellent elastic property and the ability to counteract the high pressure without the development of dilatation, calcification and degradation in the course of time. We suppose that the use of pulmonary autograft patch for surgical angioplasty of LMCA and proximal segment of RCA promotes the increase of reliability of this procedure and removes one of a lot of fears restraining a wider use of this alternative to the conventional CABG operation.

References

- [1] Hitchcock JF, Robles de Medina EO, Jambroes G. Angioplasty of the left main coronary artery for isolated left main coronary artery disease. *J Thorac Cardiovasc Surg* 1983;85:880–4.
- [2] Dion R, Puts JP, Abramowicz M. Bilateral surgical ostial angioplasty of the right and left coronary arteries. *J Thorac Cardiovasc Surg* 1991; 102(4):643–5.
- [3] Dihmis WC, Hutter JA. Ostioplasty for isolated coronary artery ostial stenosis (letter). *J Thorac Cardiovasc Surg* 1995;109:600.
- [4] Bortolotti U, Milano A, Balbarini A, Tartarini G, Levantino M, Borzoni G, Magagnini E, Mariani M. Surgical angioplasty for isolated coronary ostial stenosis. *Tex Heart Inst J* 1997;24:366–71.
- [5] Liska J, Jonsson A, Lockowandt U, Herzfeld I, Gelinder S, Franco-Cereceda A. Arterial patch angioplasty for reconstruction of proximal coronary artery stenosis. *Ann Thorac Surg* 1999;68: 2185–90.
- [6] Dion R, Verhelst R, Matta A, Rousseau M, Goenen M, Chalant Ch. Surgical angioplasty of left main coronary artery. *J Thorac Cardiovasc Surg* 1990;99:241–9. discussion 249–250.
- [7] Jegaden O, Eker A, Durand de Gevigney G, Montagna P, Ossette J, Mikaeloff P. Surgical angioplasty of the coronary trunks: an alternative to bypass techniques. *Coron Artery Dis* 1994;5:519–24.
- [8] Dion R, Elias B, Khoury GEI, Noirhomme P, Verhelst R, Hanet C. Surgical angioplasty of the left main coronary artery. *Eur J Cardiothorac Surg* 1997;11:857–64.
- [9] Chen Q, Khaddour A, Tang A, Livesey S. Surgical ostioplasty for isolated ostial stenosis of the left main stem coronary artery. *Tex Heart Inst J* 2001;28:193–5.
- [10] Beretta L, Morandi A, Lemma M, Santoli C. Surgical angioplasty for isolated left main coronary disease. In: Ghosh P, Unger F, editors. *Cardiac reconstruction*. Berlin: Springer-Verlag; 1989. p. 332–5.
- [11] Bonacchi M, Prifti E, Giunti G, Leacche M, Ballo E, Furci B, Salica A, Miraldi F, Mazzesi G, Toscano M. Mid-term outcome of surgical coronary ostial plasty: our experience. *J Card Surg* 1999;14:294–300.
- [12] Pretre R, Turina MI. Surgical angioplasty of the left main coronary artery in non-atherosclerotic lesions. *Heart* 2000;83:91–3.
- [13] Erenturk S, Yukseltan I, Demiroglu C. Transaortic coronary patchplasty for isolated main left coronary ostial stenosis: a report of five cases. *Acta Chir Belg* 1998;98:267–8.
- [14] Kapadia NK, Kapadia S, Khayat A. Left main coronary artery patch angioplasty: midterm experience and follow-up with spiral computed tomography (letter). *Ann Thorac Surg* 1999;67:1211–2.
- [15] Villemot JP, Godenir JPh, Peiffert B, Zamorano J, Chocron S, Mattei M-F, Hubert Th, Clavey M, Mathieu P. Endarterectomy of the left main coronary artery stenosis by a ‘transpulmonary artery approach’. *Eur J Cardiothorac Surg* 1988;2:453–7.
- [16] Meseguer J, Hurle A, Fernandez-Latorre F, Alonso S, Llamas P, Casillas JA. Left main coronary artery patch angioplasty: midterm experience and follow-up with spiral computed tomography. *Ann Thorac Surg* 1998;65:1594–7.
- [17] Kao CL, Chang JP, Hsieh MJ, Chang CH. Transaortic patch angioplasty for left main coronary artery occlusion. *J Formos Med Assoc* 1997;96:379–81.
- [18] Nakano S, Shimazaki Y, Kaneko M, Taniguchi K, Miyamoto Y, Takami H, Takanashi T, Matsuda H. Transaortic patch angioplasty for left coronary ostial stenosis in a patient with Takayasu’s aortitis. *Ann Thorac Surg* 1992;53:694–6.
- [19] Matsuda H, Miyamoto Y, Takahashi T, Kadoba K, Nakano S, Sano T. Extended aortic and left main coronary angioplasty with a single pericardial patch in a patient with Williams syndrome. *Ann Thorac Surg* 1991;52:1331–3.
- [20] Panza A, Masiello P, Iesu S, Triumbari F, Gigantino A, Di Leo L, Di Benedetto G. Idiopathic isolated coronary ostial stenosis: a rare lesion with particular clinical and surgical implications. *Thorac Cardiovasc Surgeon* 1995;43:40–3.
- [21] Soga Y, Okabayashi H, Shimada I, Enomoto S, Matsubayashi K, Kamikawa Y, Saitoh Y, Nagasawa A, Morimoto T. Plastic surgical reconstruction of left main coronary artery. *Jpn J Thorac Cardiovasc Surg* 1999;47:95–8.
- [22] Suma H. Left main coronary artery reconstruction by patch angioplasty (letter). *Eur J Cardiothorac Surg* 1995;9:537.
- [23] Nagy ZL, Szokol M, Peterffy A. Direct ostioplasty of the main coronary artery using the right internal thoracic artery as patch material. *Eur J Cardiothorac Surg* 2001;20:1233–4.
- [24] Moro H, Hayashi J, Nakayama T. Patch angioplasty of left main coronary artery (letter). *Ann Thorac Surg* 1999;67:1209–18.
- [25] Goor DA, Lillehei CW. Congenital malformations of the heart. Embryology, anatomy, and operative considerations. New York San Francisco London: Grune & Stratton; 1975. p. 80–1.

Surgical angioplasty of the left main coronary artery and/or proximal segment of the right coronary artery by pulmonary autograft patch

Michael Malyshev, Igor Gladyshev, Alexander Safuanov, Dmitry Siniukov, Dmitry Borovikov and Natalie Rostovykh

Eur J Cardiothorac Surg 2004;25:21-25

DOI: 10.1016/j.ejcts.2003.09.017

This information is current as of July 11, 2010

Updated Information & Services	including high-resolution figures, can be found at: http://ejcts.ctsnetjournals.org/cgi/content/full/25/1/21
References	This article cites 23 articles, 13 of which you can access for free at: http://ejcts.ctsnetjournals.org/cgi/content/full/25/1/21#BIBL
Citations	This article has been cited by 3 HighWire-hosted articles: http://ejcts.ctsnetjournals.org/cgi/content/full/25/1/21#otherarticles
Subspecialty Collections	This article, along with others on similar topics, appears in the following collection(s): Coronary disease http://ejcts.ctsnetjournals.org/cgi/collection/coronary_disease
Permissions & Licensing	Information about reproducing this article in parts (figures, tables) or in its entirety can be found online at: http://ejcts.ctsnetjournals.org/misc/Permissions.shtml
Reprints	Information about ordering reprints can be found online: http://ejcts.ctsnetjournals.org/misc/reprints.shtml

EUROPEAN JOURNAL OF
**CARDIO-THORACIC
SURGERY**